

الجامعة السورية الخاصة
كلية الطب البشري
قسم الجراحة

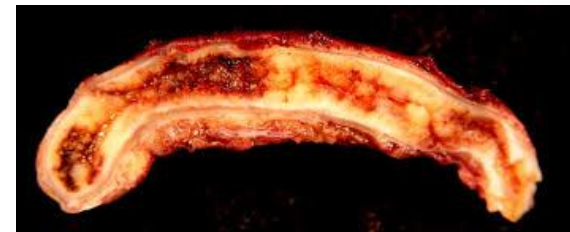
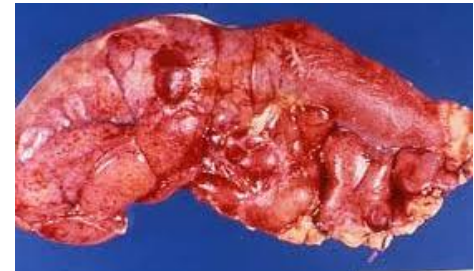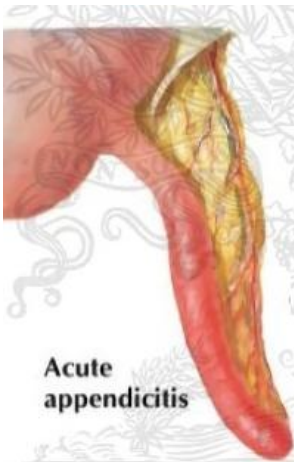
التهاب الزائدة الحاد

Acute Appendicitis

أ.د. عاصم قبطان MD - FRCS

Introduction

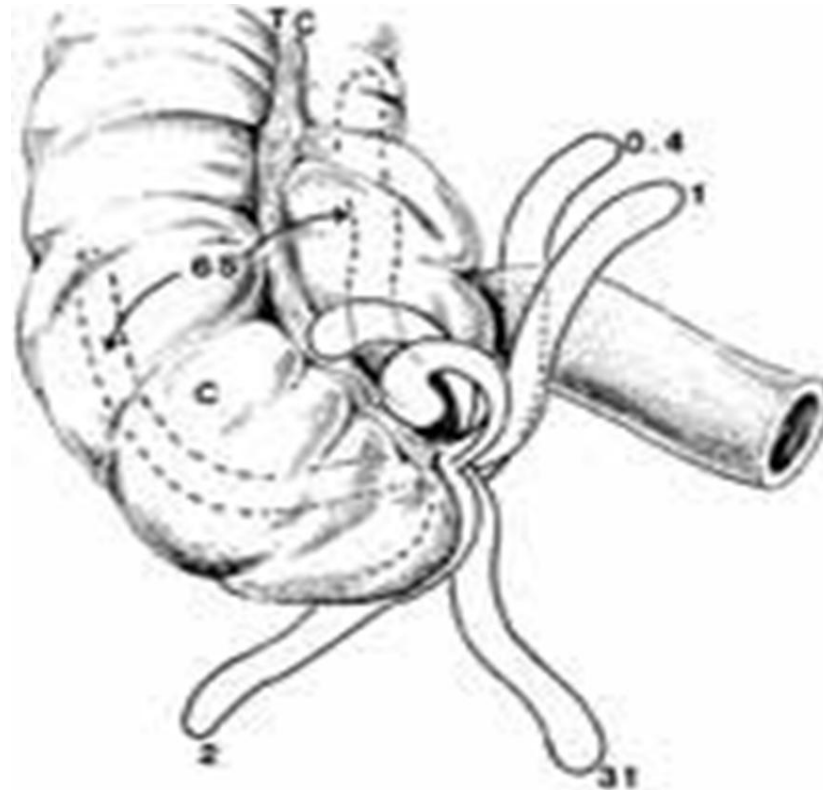
Appendix is a blind intestinal diverticulum (6-10 cm) in length arises from the postero medial aspect of the caecum inferior to the ileocaecal junction origin where it arises from the site at which the three Tania coli collect. The appendix has short Mesentery (The Meso-appendix).



Anatomical Varieties

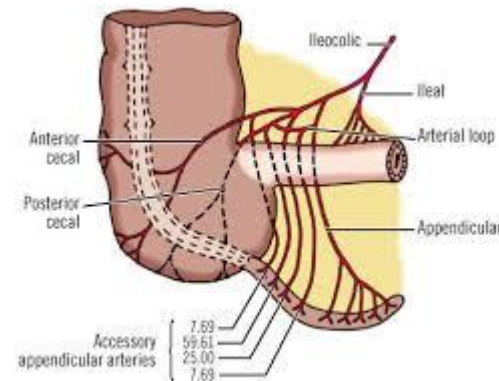
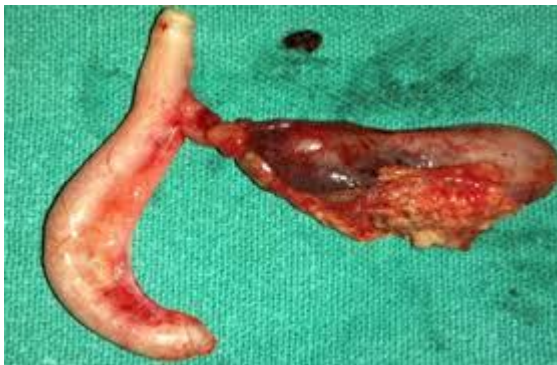Retrocecal -- right pericolic position -- subcecal -- peri-ileal -- pelvic

Length range 1-30 cm with average 6-9.



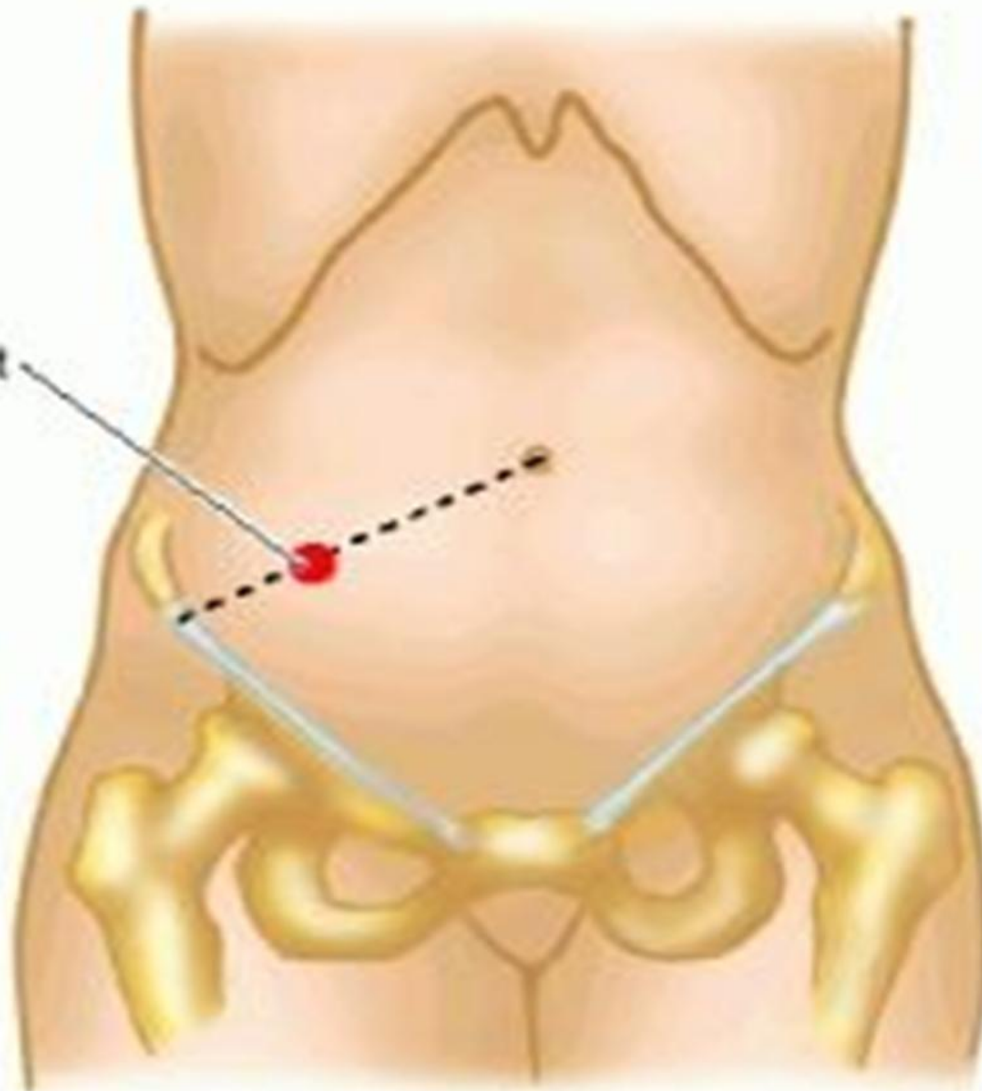
Surgical Anatomy

- Congenital absence – rare 68 cases reported
- Duplication - <100 cases
- Blood supply – appendiceal artery (end artery) – ileocolic – SMA



Copyright ©2006 by The McGraw-Hill Companies, Inc.
All rights reserved.

McBurney point



The function of the appendix

- In the early childhood life till the age of three the appendix has a special rule in the development of the lymphoid tissues in it's wall relating to the immunological function of the organ
- لها علاقة بتشكيل الجهاز المناعي .
- So far there is no known function of the appendix after the childhood period .
- The function of the appendix in adolescence and adult stages is regressed including lymphoid tissues regression
- تراجع في دور الجهاز المناعي في مرحلة اليافع .
- In the elderly. The appendix lumen usually become obliterated by fibrosis.

Definition

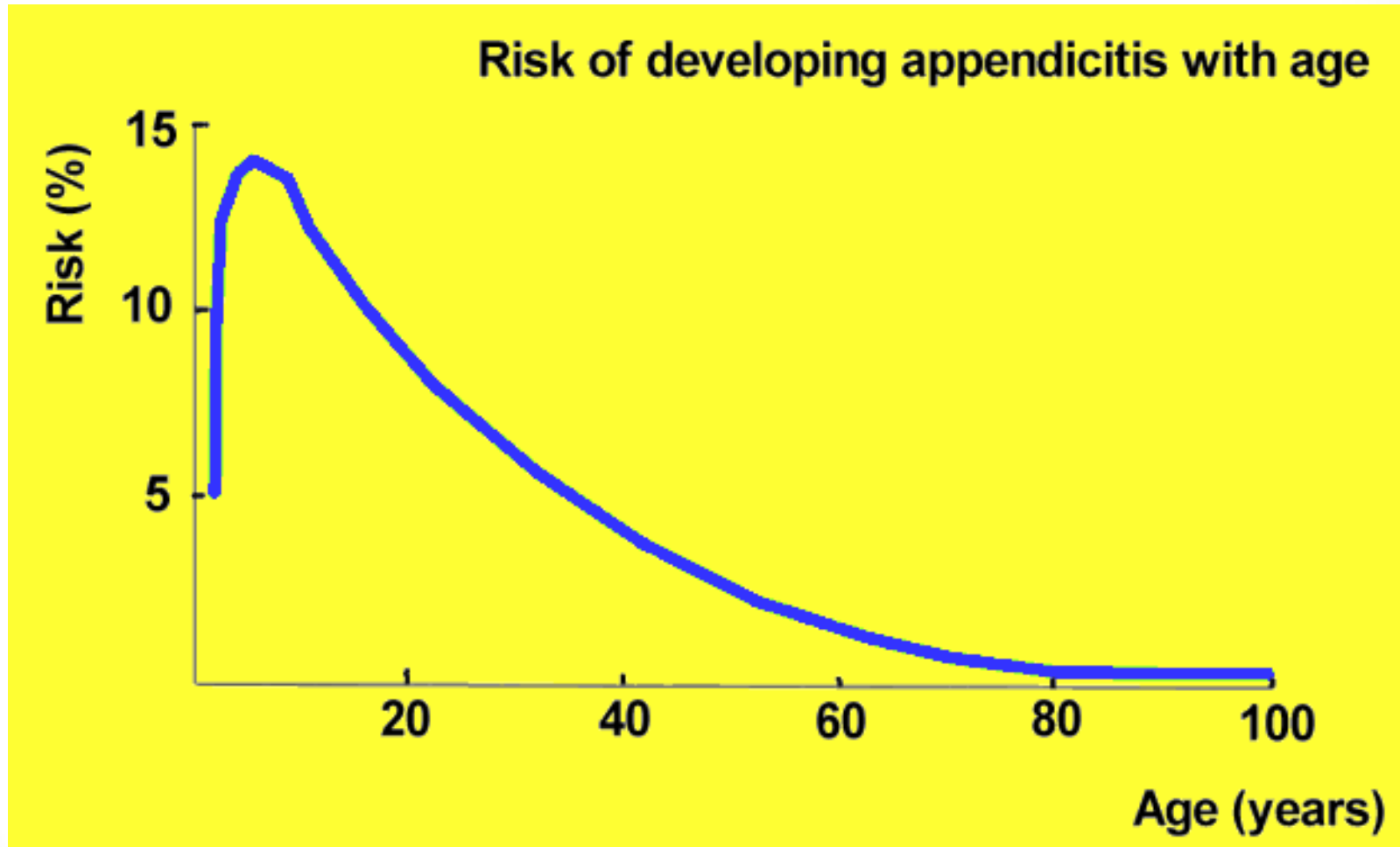
حالة التهابية حادة مفاجئة تحدث بسبب انسداد في لمعة الزائدة
ينتج عنها غزو للعناصر الجرثومية القرنة في الأمعاء

Sudden inflammation of the appendix usually caused by obstruction of the lumen resulting in invasion of the appendix wall by the gut flora

Epidemiology

- RIF pain is common – 50% of acute abdo pain
- ألم في الحفرة الحرقفية اليمنى
- Accounts for 2% of all hospital admissions
- 7-12% of population
- >70,000 appendicectomies per year UK
- Incidence decreasing
- M>F
- Age

Age



Incidence of Acute Appendicitis

- Acute appendicitis is the most common acute surgical emergency of the abdomen.
- The disease occurs at all ages but most frequently below age 40 years specially, between the ages 8-14. It is very rare below the age of two.
- The sex ratio is 1:1 prior to puberty , adult M:F, 2:1. However the incidence is decreased for last 10 years. This may be due to better diagnosis, changing in dietary habits.

Pathophysiology

- Acute appendicitis is thought to begin with obstruction of the lumen
- Obstruction can result from food matter, adhesions, or lymphoid hyperplasia
- Mucosal secretions continue to increase intraluminal pressure
- Eventually the pressure exceeds capillary perfusion pressure , venous and lymphatic drainage are obstructed.
- With vascular compromise, epithelial mucosa breaks down and bacterial invasion by bowel flora occurs.
- Increased pressure also leads to arterial stasis and tissue infarction
- End result is perforation and spillage of infected appendiceal contents into the peritoneum

Pathophysiological aspects of Symptoms

- Initial luminal distention triggers visceral afferent pain fibers, which enter through the 10th thoracic spinal nerve .
- This pain is generally vague and poorly localized.
- Pain is typically felt in the periumbilical or epigastric area.
- As inflammation continues, the serosa and adjacent structures become inflamed
- This triggers somatic pain fibers, innervating the peritoneal structures.
- Typically causing pain in the RLQ
- The change in stimulation from visceral to somatic pain fibers explains the classic migration of pain in the periumbilical area to the RLQ seen with acute appendicitis.

Variation in Symptoms

- Exceptions exist in the classic presentation due to anatomic variability of the appendix
- Appendix can be retrocecal causing the pain to localize to the right flank
- In pregnancy, the appendix can be shifted and patients can present with RUQ pain
- In some patients , retroileal appendicitis can irritate the ureter and cause testicular pain.
- Pelvic appendix may irritate the bladder or rectum causing suprapubic pain, pain with urination, or feeling the need to defecate
- Multiple anatomic variations explain the difficulty in diagnosing appendicitis

Bacteriology

- Bacteria cultured in cases of appendicitis are similar to those seen in other colonic infection.
- The principal organisms seen are *E. coli* and *Bacteroid fragilis*

Clinical Manifestation

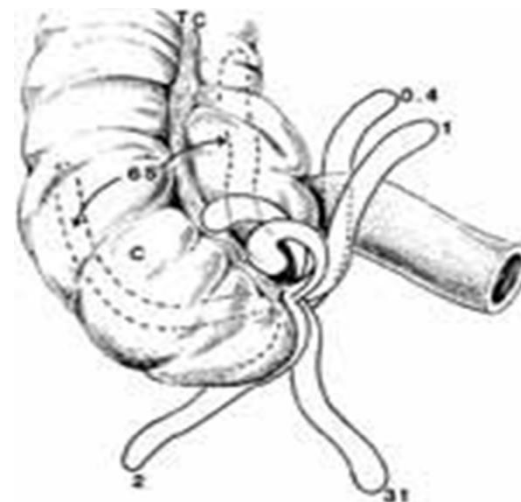
Symptoms

Primary symptom: abdominal pain

½ to 2/3 of patients have the classical presentation

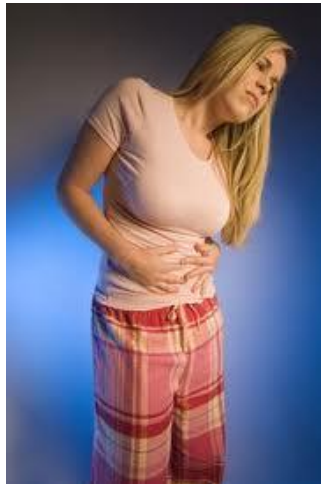Pain: Pain beginning in epigastrium or periumbilical area that is vague and hard to localize , begins as visceral pain diffuse steady moderately severe epigastric or periumbilical pain, sometimes accompanied by intermittent crampy pain. Then, shifting of to localized pain in RLQ manifest the somatic component. Somatic pain depends on the location of the tip of the appendix.

- LLQ → LLQ pain
- Retrocecal → flank or back pain
- Pelvic → suprapubic pain
- Retroileal → testicular pain



Associated symptoms

- Indigestion, discomfort, flatus, need to defecate, anorexia, nausea, vomiting
- As the illness progresses RLQ localization typically occurs
- RLQ pain was 81 % sensitive and 53% specific for diagnosis



Continue

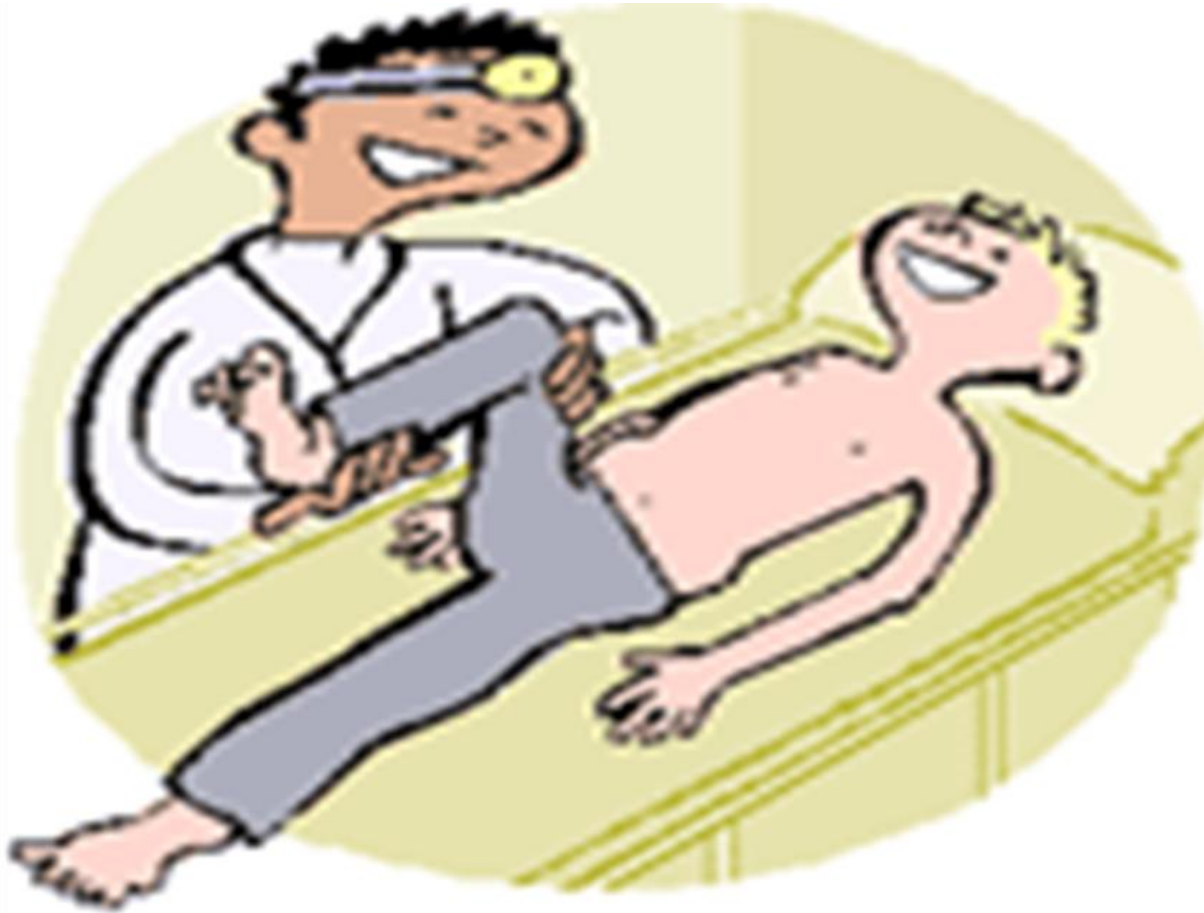- **Anorexia:** nearly always
- **Vomiting:** once or twice
- **Obstipation:** prior to the onset of the pain. Some might c/o diarrhea.

Clinical features - Signs

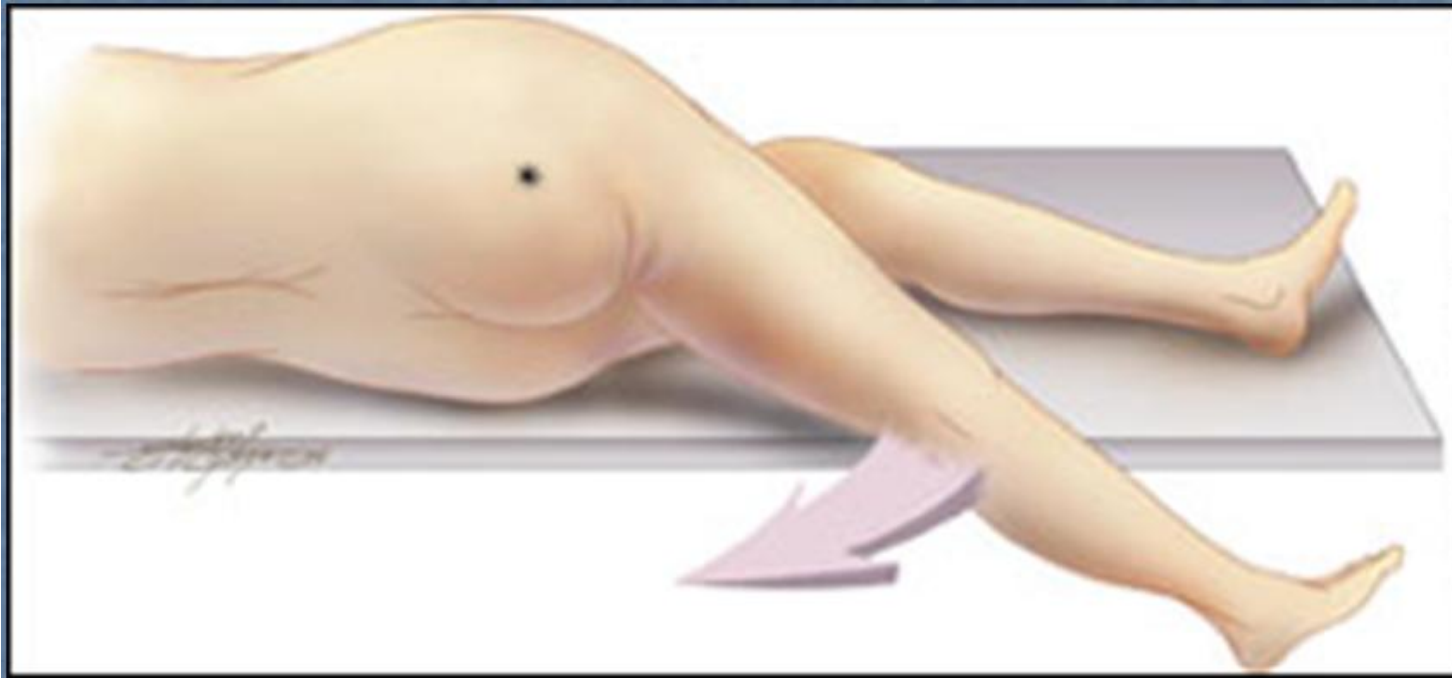
- RIF tenderness Guarding
- Percussion tenderness (rebound)
- Rigidity
- Guarding
- Tachycardia
- Brown-furred (محتقن غاضب) tongue
- Foul Breath

Signs

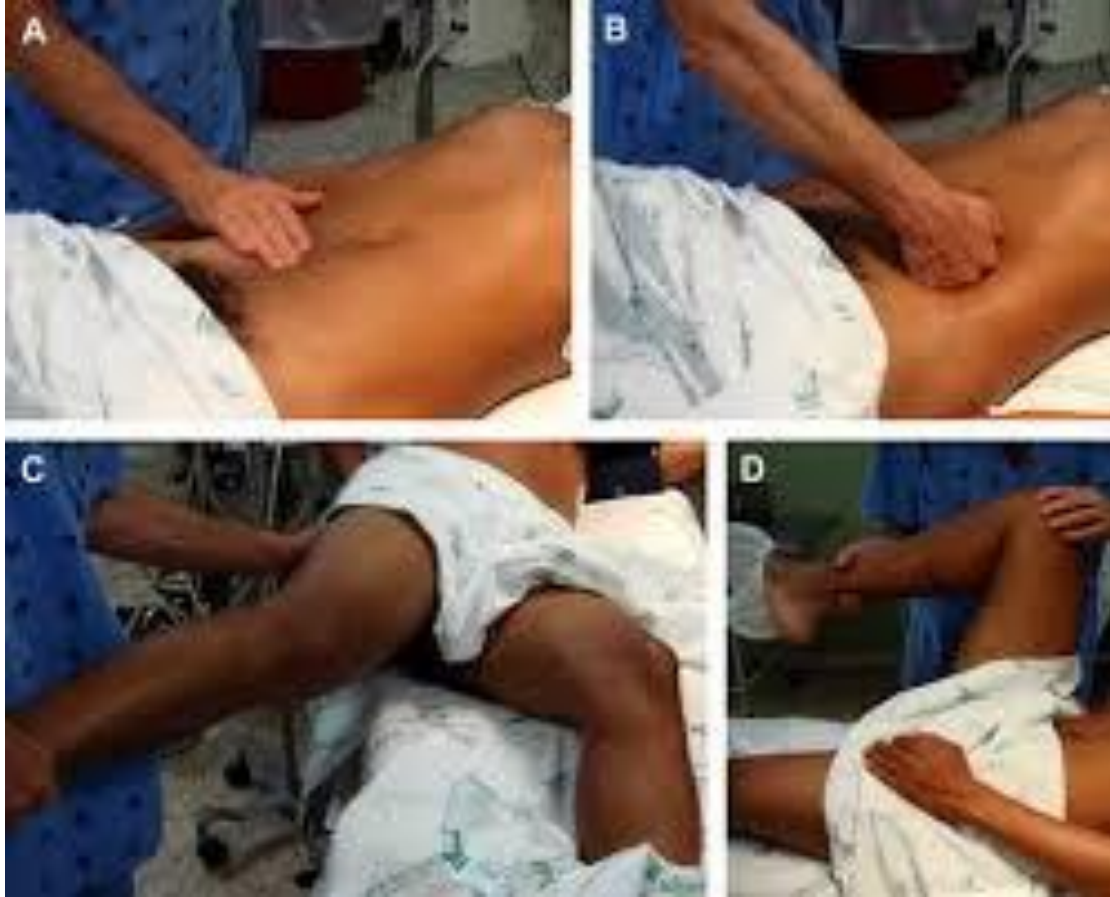- **VS** : minimally changed by uncomplicated appendix. If not think of either complicated appendicitis or other diagnosis.
- Patient prefers to stay in R thigh flexion position.
- McBurney's point tenderness and rebound tenderness.
- Rovsing's sign
- Cutaneous hyperesthesia T10,11,12.
- Psoas sign
- obturator sign.
- Guarding and rigidity appear with more severe inflammatory process.
- Retrocecal : tenderness more in the flank.
- Pelvic: painful rectal exam.



obturator sign.



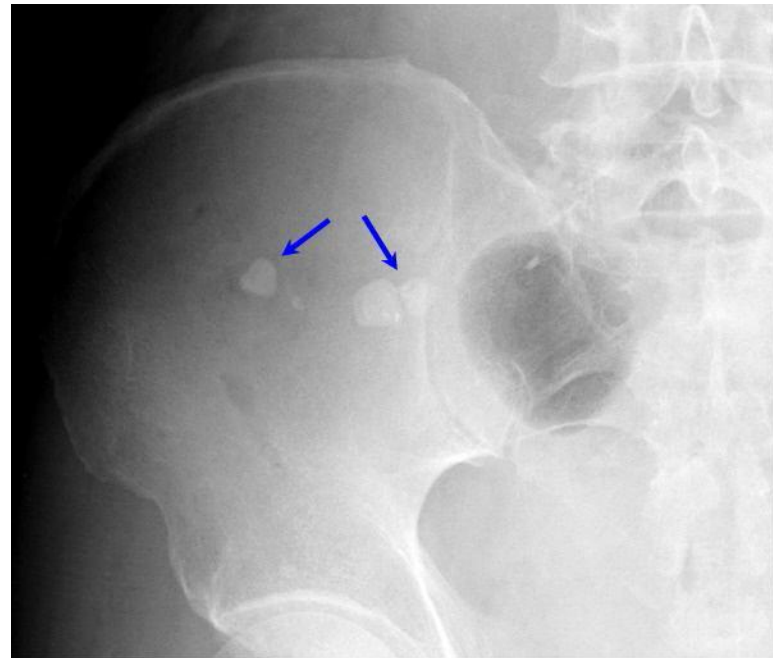
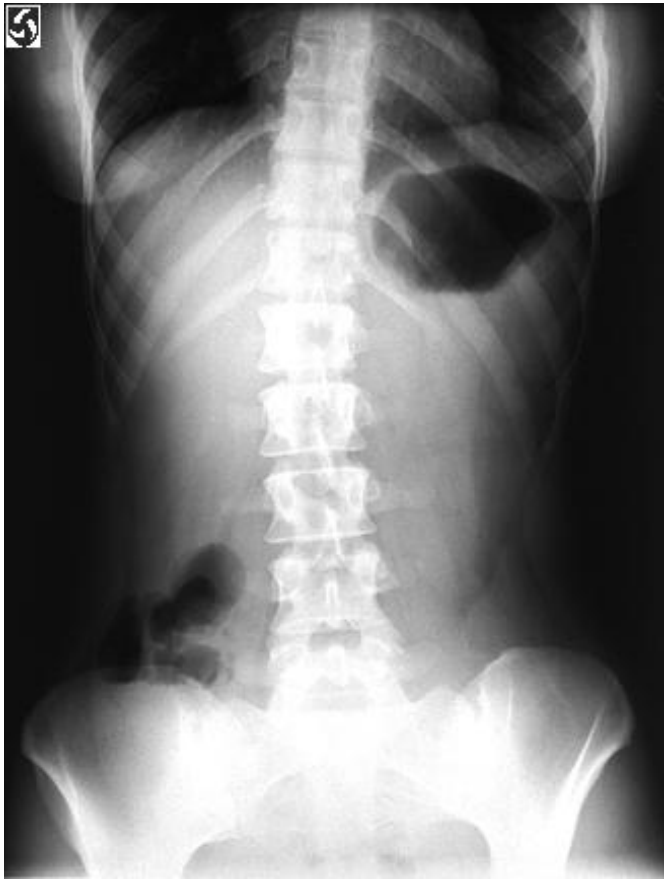
Psoas sign



Investigations

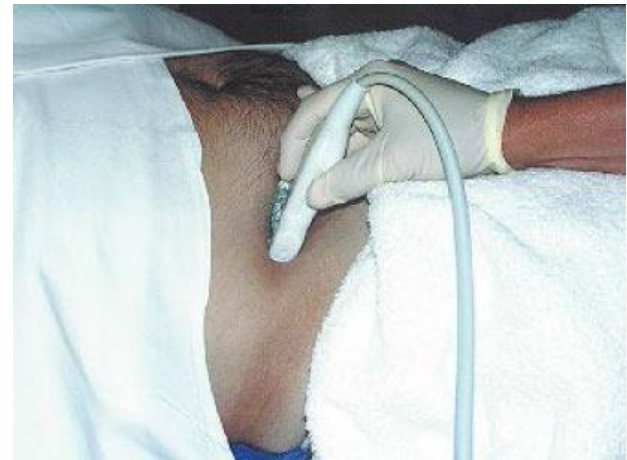- WCC – 70% - 90% - elevated WCC.
- Neutrophilia
- CRP
- Urinalysis – pyuria/haematuria (do not exclude appendicitis)
- HIT
- AXR – limited value

Abdominal X-ray



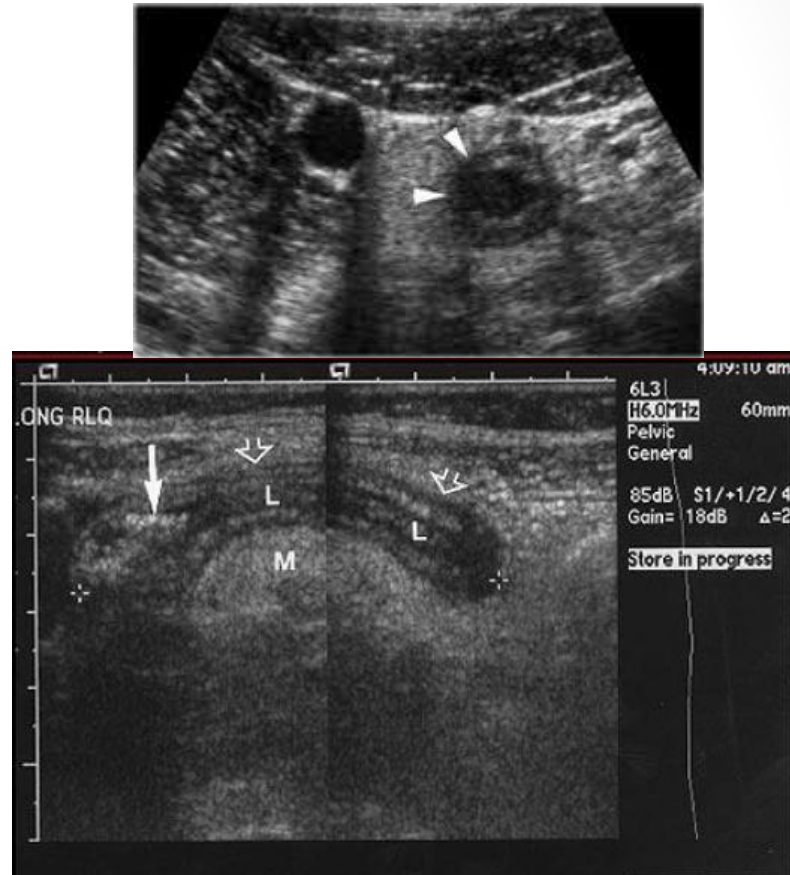Graded compression Ultrasound

- Depends on the technique and experience
- Thin pts better
- Normal appendix a blind-ended, tubular structure with a maximum wall thickness of 2 mm with an outer diameter of 6 mm.
- No peristalsis
- Originates from the base of the cecum



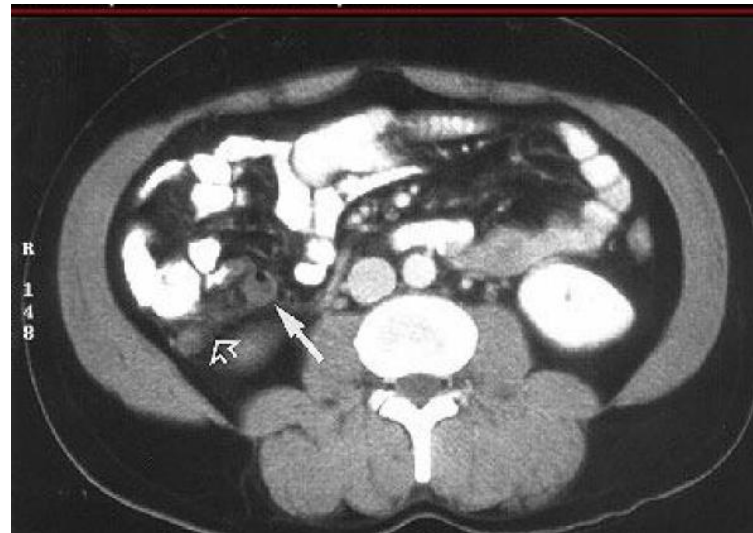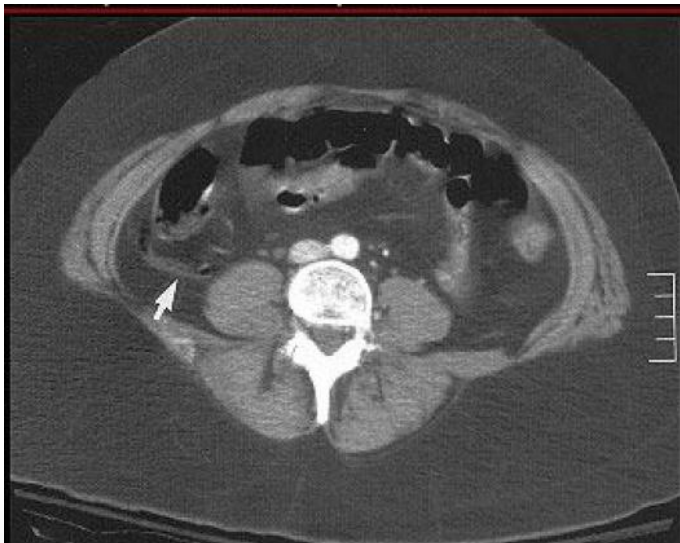
Graded compression Ultrasound

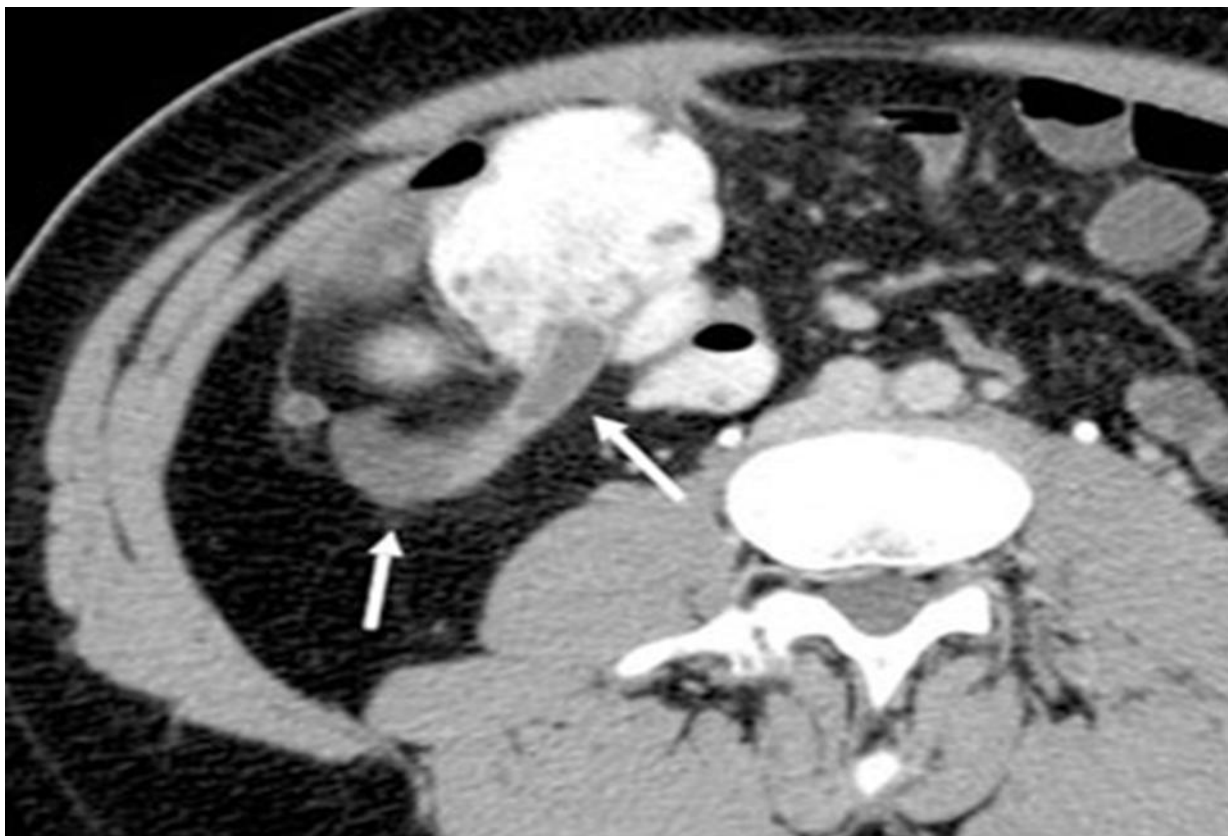- Thickened wall >3 mm
- Diameter >6 or 7 mm
- Noncompressible
- Appendolith
- Circumferential color flow
- Echogenic mesentery
- Free fluid
- Abscess



CT

- variable degree of distension (diameter 6–40 mm)
- wall thickness of 1–3 mm.
- Wall - asymmetrically thickened enhances with intravenous contrast medium. periappendiceal inflammatory mass
- Thickening and enhancement with intravenous contrast - adjacent wall of the cecum or ileum





Differential diagnosis

- **GIT**

- Gastroenteritis
- Mesenteric adenitis
- Intestinal obstruction
- Meckle's diverticulitis
- Terminal ileitis (Crohn's, *Yersinia enterocolytica*)
- Ca Caecum
- Sigmoid diverticulitis
- Acute typhlitis
- Cholecystitis
- Perf ulcer

Differential diagnosis

- **Gynae**

- Salpingitis
- Ectopic gestation
- Rt Ovarian torsion
- Ruptured ovarian follicle (Mittelschmerz)

Differential diagnosis

- **Urinary tract**

- Renal colic
- Pyelonephritis
- Testicular torsion

Differential diagnosis

- **Others**

- Referred pain (Pneumonia, pleurisy)
- Preherpetic neuralgia
- Porphyria
- Henoch Schonlein syndrome
- Pancreatitis
- Rectus sheath haematoma

Problem Areas in Diagnosis

- Appendicitis in infancy.
- Appendicitis during pregnancy.
- Appendicitis in the elderly
- Appendicitis developing in hospital

Complications of Acute Appendicitis

- Pre-operative complications
- Post-operative complications

Pre-operative complications

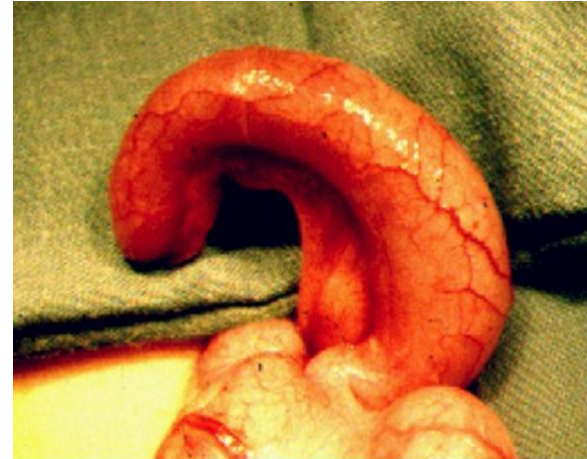- Perforation
- Appendicular abscess
- Portal pyaemia
- Peritonitis

Post-operative complications

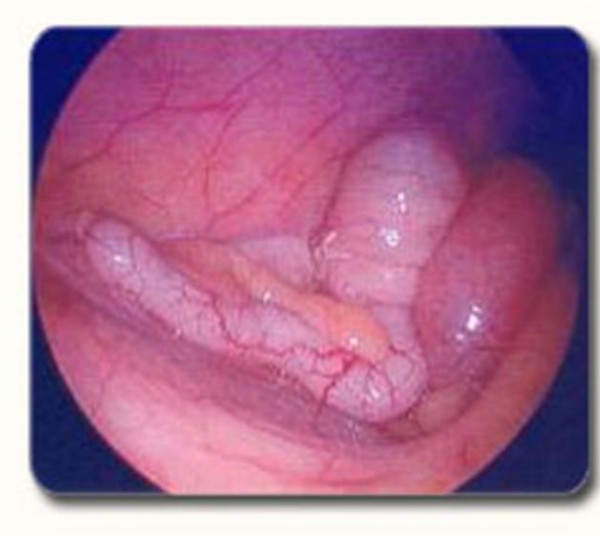- Bleeding
- Urinary retention
- Wound infection
- Intra peritoneal abscess
- Post app. Fistula
- Intestinal obstruction

Treatment of Acute Appendicitis

Emergency Open Surgical Appendicectomy .



Emergency Laparoscopic Appendicectomy .



Conservative Treatment

Is indicated when a palpable mass is present in RIF

Interval appendectomy done at least 6 weeks following the acute event.

It is contra indicated in the following condition.

- Children below 10 years of age
- Elderly patients
- Diabetic patients
- Doubtful diagnosis

The End